

Use of an intragastric trocar to perform a novel stapling procedure for reflux disease ▶



Authors

Andrew C. Storm^{1,2}, Jad P. AbiMansour¹, Aliana Bofill-Garcia¹, Tala Mahmoud¹, Babusai Rapaka¹, Kristin E. Lescalleet¹, Barham K. Abu Dayyeh¹

Institutions

- 1 Division of Gastroenterology and Hepatology, Mayo Clinic, Rochester, Minnesota, United States
- 2 Developmental Endoscopy Unit, Mayo Clinic, Rochester, Minnesota, United States

submitted 4.5.2022

accepted after revision 25.8.2022

published online 30.8.2022

Bibliography

Endosc Int Open 2022; 10: E1508–E1513

DOI 10.1055/a-1933-6573

ISSN 2364-3722

© 2022. The Author(s).

This is an open access article published by Thieme under the terms of the Creative Commons Attribution-NonDerivative-NonCommercial License, permitting copying and reproduction so long as the original work is given appropriate credit. Contents may not be used for commercial purposes, or adapted, remixed, transformed or built upon. (<https://creativecommons.org/licenses/by-nc-nd/4.0/>)

Georg Thieme Verlag KG, Rüdigerstraße 14,
70469 Stuttgart, Germany

Corresponding author

Andrew C. Storm, M.D., 200 First St. SW, Rochester, MN,
United States

Phone: +1-507-775-6930

storm.andrew@mayo.edu

ABSTRACT

Background and study aims A percutaneous intragastric trocar (PIT) enables intraluminal use of laparoscopic tools and helps overcome traditional limitations of endoscopy. The aim of this study was to determine the efficacy of using a PIT to perform an anti-reflux stapling procedure.

Materials and methods Trocars were placed in four animals and an articulating stapler was used to perform fundoplication under endoscopic guidance. Animals were monitored for 14 days post-procedure. Functional lumen imaging of the esophagogastric junction (EGJ) was performed at baseline, immediately post-intervention, and at 14 days.

Results The procedure was successful in all animals who survived to day 14 without distress or significant adverse events. Baseline EGJ distensibility was $5.0 \pm 1.2 \text{ mm}^2/\text{mmHg}$, $2.7 \pm 0.7 \text{ mm}^2/\text{mmHg}$ post-procedurally, and $3.0 \pm 0.8 \text{ mm}^2/\text{mmHg}$ on day 14. Average change in distensibility pre- and post-procedure was $-2.3 \pm 1.8 \text{ mm}^2/\text{mmHg}$ (95% confidence interval [CI] -0.5 to 5.1 , $P=0.08$) while change in pre- and day 14 distensibility was $-2.0 \pm 1.4 \text{ mm}^2/\text{mmHg}$ (95% CI -0.1 to 4.2 , $P=0.06$).

Conclusions An intragastric trocar allows for use of large-diameter laparoscopic instruments to safely and effectively perform endoluminal fundoplication with anti-reflux properties that persist for at least 14 days.

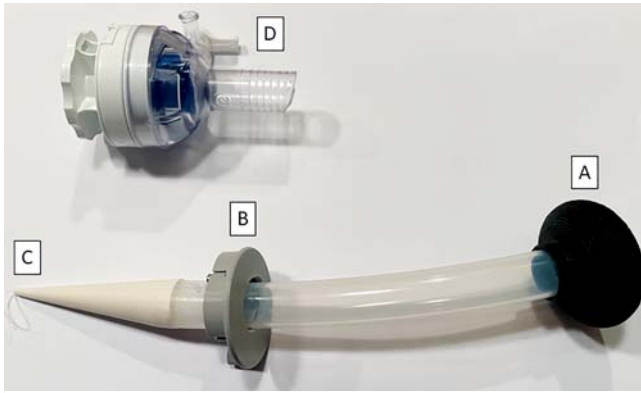
Introduction

The field of therapeutic endoscopy has grown exponentially over the past two decades with the refinement of endoscopic techniques and advances in biotechnology. However, endoscopic procedures continue to be limited by positioning, triangulation, and constraints on instrument size. The use of a novel percutaneous intragastric trocar (PIT) can facilitate completion of complex endoscopic interventions by providing endoluminal access for a variety of instruments, particularly those previously restricted to surgical applications.

A PIT (endo-TAGSS LLC, Shawnee, Kansas, United States) can be placed using a technique analogous to pull-through placement of a percutaneous endoscopic gastrostomy tube, essen-

tially creating a fully functional laparoscopic port (▶ **Fig. 1**). The device provides endoluminal access for large-diameter instruments. The design, placement, and use of a PIT has been described previously [1–3]; however, its clinical applicability has not been well established.

Anti-reflux surgery, typically through open or laparoscopic fundoplication, has been the longtime gold-standard for refractory gastroesophageal reflux disease (GERD) treatment. There has been great interest in less invasive treatment options, and over the past two decades, multiple endoscopic techniques have emerged including radiofrequency ablation, mucosal resection, and transoral incisionless fundoplication (TIF). Currently, TIF is the only procedure conditionally recommended, albeit with a low level of evidence, in patients with mild reflux



► **Fig. 1** Components of the percutaneous intragastric trocar including: **a** internal bumper; **b** adjustable external bumper; **c** loop to secure pull-through; and **d** fully functioning 12-mm laparoscopic port.

who do not wish to undergo surgery [4]. However, widespread adoption has been limited due to the need for a dedicated fundoplication device, multiple technical modifications since its introduction, and mixed long-term efficacy and cost-effectiveness data [5].

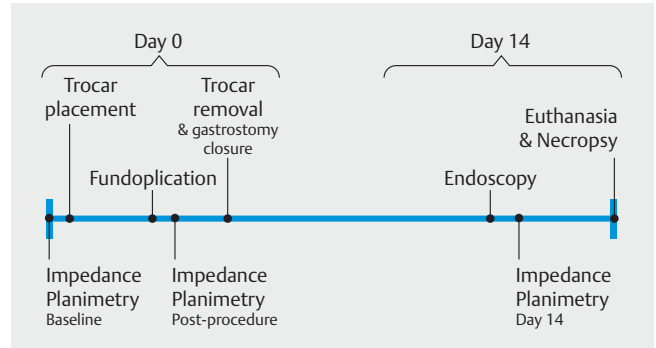
The emergence of functional lumen imaging has also impacted the way GERD is managed both endoscopically and surgically. The technology allows for real-time assessment of esophagogastric junction (EGJ) distensibility, and there is significant interest in using these data to optimize anti-reflux surgery and predict outcomes [6]. While additional studies are needed to fully determine its clinical utility, distensibility of the EGJ has shown to decrease after surgical fundoplication [7, 8] and TIF [9, 10].

The goal of this porcine survival study was to evaluate the feasibility of an anti-reflux procedure performed with laparoscopic devices introduced through a PIT. The procedure incorporates concepts from endoscopic fundoplication, and functional lumen imaging data are used to highlight potential anti-reflux mechanisms.

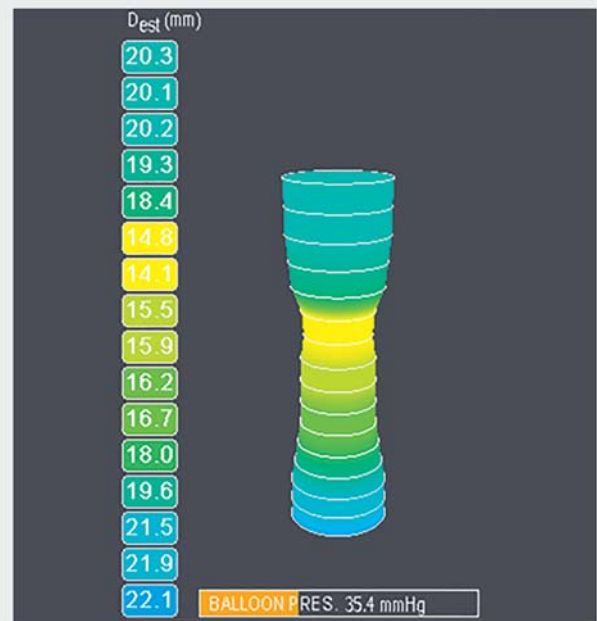
Materials and methods

Animal studies

Four domestic pigs (weight range 42–47 kg) were studied following the American Physiological Society guidelines for the care and use of animals and a protocol approval by the Mayo Clinic Institutional Animal Care and Use Committee. The animals were started on a liquid diet 48 hours prior to the procedure followed by a clear liquid diet 24 hours prior. They were kept nil per os on the day of intervention. Induction was performed with intramuscular telazol 5 mg/kg and xylazine 2 mg/kg, followed by intubation and mechanical ventilation with 2% isoflurane maintenance anesthesia.



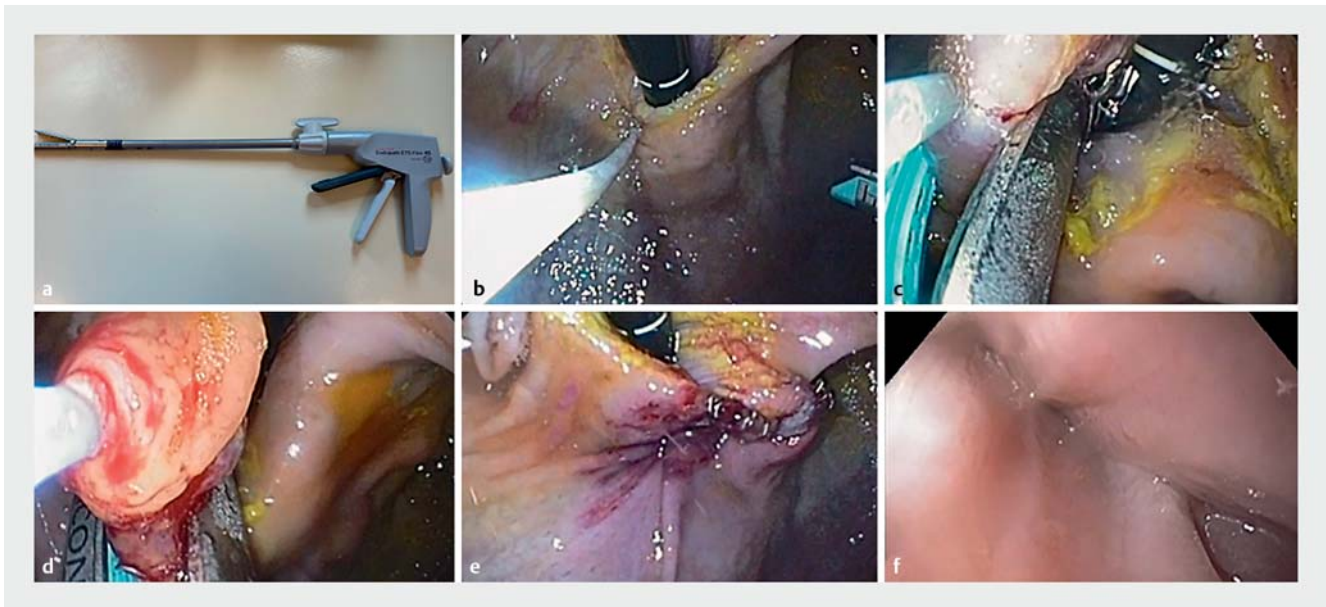
► **Fig. 2** Study design and timing of interventions.



► **Fig. 3** An example of impedance planimetry used to measure EGJ diameter which is ultimately used to calculate distensibility index.

Esophagogastric junction distensibility

Functional lumen imaging data were obtained pre-procedure, immediately post-procedure, and on day 14 (► **Fig. 2**). An 8-cm measurement catheter equipped with a pressure transducer (Endoflip Measurement Catheter, Medtronic, Minneapolis, Minnesota, United States) was placed across the EGJ under endoscopic guidance. The catheter was distended in 10 mL increments using a proprietary fluid and the catheter was centered over the EGJ. Measurements were obtained at a distension volume of 40 mL in all animals. Area and distensibility were automatically calculated by the impedance planimetry system (Endoflip 2.0 Impedance Planimetry System, Medtronic, Minneapolis, Minnesota, United States) after distension was maintained for a minimum of 30 seconds. Generally, the device calculates EGJ area using Ohm's law (► **Fig. 3**). A distensibility index could then be derived by dividing the minimum cross-sectional



► **Fig. 4** **a** Articulating stapler used for tissue apposition. **b** Tissue from the gastric cardia retracted using helical tissue grasper. **c** Stapler deployment once tissue is retracted. **d** Additional deployment of stapler to create flap valve. **e** Gastroesophageal junction seen in retroflexion on completion of warp. **f** Antegrade view with gastroscop demonstrating narrowing of the junction.

tional area by pressure. After measurements were completed, the balloon was deflated and removed.

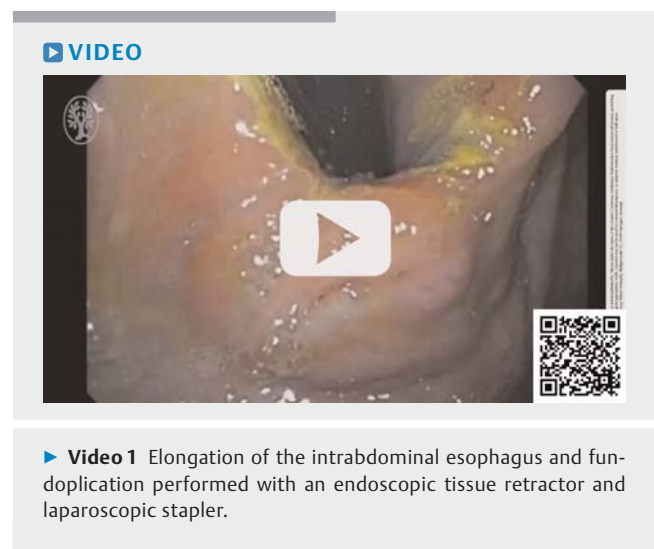Average distensibility measurements at baseline, post-procedure, and day 14 are reported with mean and standard deviation. Changes in distensibility from baseline to post-procedure as well as baseline to day 14 were compared using two-sided, paired *t*-tests reported with a 95% confidence interval (CI). Statistical analysis and data visualization was performed with BlueSky Statistics software v.7.10 (BlueSky Statistics LLC, Chicago, Illinois, United States).

Trocar placement

A PIT was inserted using a technique analogous to placement of a pull-through percutaneous endoscopic gastrostomy tube. A site immediately contralateral to and facing the EGJ was selected using endoscopic visualization, transillumination, and palpation. The skin was cleaned with chlorhexidine and an introducer needle was inserted into the stomach under endoscopic guidance. A wire was advanced, snared, removed transorally, and attached to the trocar. After a small cutaneous incision was made to facilitate device passage through the skin, the PIT was pulled into the stomach and through the gastric and abdominal walls. The device was secured with an external bumper and a fully functioning, 12-mm laparoscopic port was attached to complete device assembly.

Fundoplication, trocar removal, and gastrostomy closure

A diagnostic gastroscope (Olympus, Tokyo, Japan) with carbon dioxide insufflation was used to visualize insertion of a 12-mm articulating and non-cutting stapler (Ethicon Inc., Raritan, New



► **Video 1** Elongation of the intrabdominal esophagus and fundoplication performed with an endoscopic tissue retractor and laparoscopic stapler.

Jersey, United States) into the stomach through the PIT. The stomach was insufflated with carbon dioxide and the gastroscope placed into retroflexion to examine the EGJ. A helical tissue grasper (Helix, Apollo Endosurgery, Austin, Texas, United States) was used to secure and retract tissue into the jaws of the stapler, which was controlled by a second operator. Tissue was retracted caudally to increase the length of the intra-abdominal esophagus as well as rotated to create a functional flap valve (► **Fig. 4** and ► **Video 1**).

After completion of the procedure, functional lumen imaging was repeated as described above to obtain immediate post-procedure measurements. Finally, a gastroscope fitted with an over-the-scope clip (OTSC) was reintroduced into the

stomach and the PIT was removed with gentle external traction. Gastric tissue was approximated using twin graspers (OTSC Twin Grasper, Ovesco Endoscopy, Tübingen, Germany) and a 14.6-mm OTSC (Ovesco Endoscopy, Tübingen, Germany) was deployed to close the gastrostomy site. The cutaneous incision was closed with non-absorbable suture and a topical skin adhesive.

Survival and necropsy

The animals were started on a liquid diet for 24 hours post-procedure followed by a soft diet for an additional 24 hours before resuming a regular mash diet and daily proton pump inhibitor. They were monitored for a total of 14 days and assessed daily for pain or distress. On day 14, an upper endoscopy was repeated to assess the fundoplication and gastrostomy closure site prior to euthanasia with intravenous pentobarbital. Necropsy was performed with particular attention to trocar site healing, presence of adhesions, signs of intra-abdominal infection, perforation, and fundoplication durability.

Results

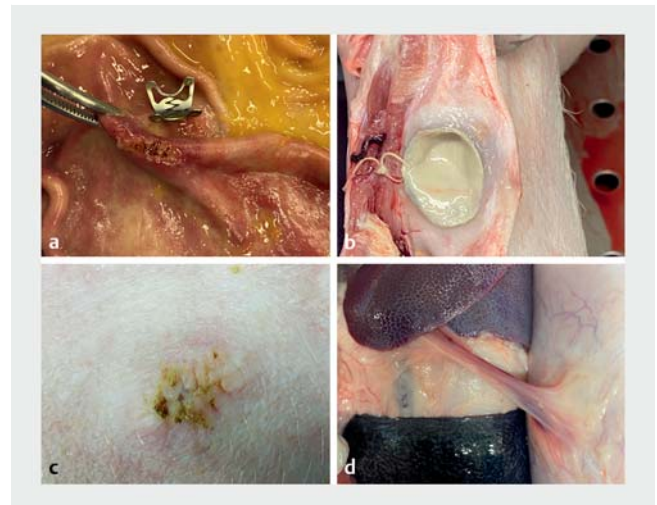
Trocar placement, fundoplication, and gastrostomy site closure were performed successfully in all four animals without immediate complications. All pigs survived to postoperative day 14 without evidence of pain or distress. No animal required administration of analgesics, antibiotics, or early euthanasia. On day 14, all endoscopic examinations revealed a tight EGJ, functioning flap valve, and intact fundoplication. Gastrostomy sites appeared well healed with in-situ OTSC in three of the four cases (75%). In one case where the clip was seen partially detached, healing of the gastrostomy site had still occurred (► Fig. 5a).

One pig was noted to have mild fluctuance at the incision site. Necropsy revealed the presence of a 2-cm purulent collection consistent with a subclinical, cutaneous abscess in this animal (► Fig. 5b). All other incisions appeared clean and well healed (► Fig. 5c). Gastropexy to the anterior abdominal wall was seen in three cases (75%) (► Fig. 5d). There was no evidence of intra-abdominal abscess, perforation, or peritonitis.

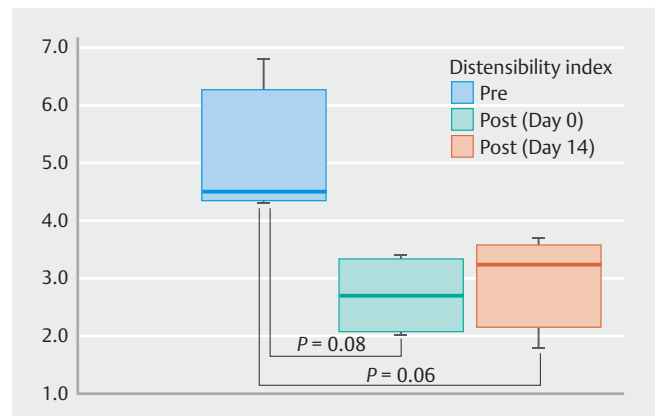
Baseline, post-procedure, and day 14 distensibility measurements were performed successfully in all cases (► Fig. 6). Mean distensibility was $5.0 \pm 1.2 \text{ mm}^2/\text{mmHg}$ at baseline, $2.7 \pm 0.7 \text{ mm}^2/\text{mmHg}$ post-procedure, and $3.0 \pm 0.8 \text{ mm}^2/\text{mmHg}$ on day 14. Average change in distensibility pre- and post-procedure was $-2.3 \pm 1.8 \text{ mm}^2/\text{mmHg}$ (95% CI -0.5 to 5.1 , $P=0.08$) while the average change in pre- and day 14 distensibility was $-2.0 \pm 1.4 \text{ mm}^2/\text{mmHg}$ (95%CI -0.1 to 4.2 , $P=0.06$).

Discussion

This porcine survival study demonstrates the feasibility of utilizing a PIT to perform an anti-reflux procedure with a 12-mm laparoscopic stapler. Despite advances in therapeutic endoscopic techniques, interventions continue to be limited by the need for flexible and relatively small diameter devices to accommodate the endoscope and patient anatomy. Prior attempts to



► Fig. 5 Necrosectomy findings including: a gastric closure site; b a suture abscess in one animal; c skin closure site; and d mild adhesive disease.



► Fig. 6 Box plot of pre, post, and day 14 distensibility measurements showing interquartile range and median as horizontal bar. Vertical lines represent minimum and maximum values. P values shown for two-sided paired t-test.

overcome these limitations resulted in a technique initially termed “laparoscopic intragastric surgery” [11]. The approach utilized both intragastric and intraperitoneal trocars for excision of benign and early malignant lesions of the stomach, with data suggesting modest improvement in length of stay, procedural blood loss, and overall morbidity [12–15].

The technique described in the current study obviates the need for traditional laparoscopic trocar placement and visualization, theoretically improving the safety profile of the combined approach, which can now be performed in a non-sterile endoscopy setting. It also allows for easy access and control of larger devices in ways that would never be feasible through an endoscopic approach alone, while eliminating the need to develop and train endoscopists on specialized TIF platforms as the percutaneous gastrostomy paradigm is well understood by most endoscopists.

Further studies are needed to determine where this hybrid procedure would be best positioned among existing therapeutic options for GERD. The past decade has resulted in novel techniques to address pathologies that were previously managed exclusively with surgery, such as TIF for GERD and peroral endoscopic myotomy for achalasia. These endoscopic approaches have established themselves as treatment options alongside of and not as a replacement for surgery. Each approach has its own risks, benefits, and indications – and the exact procedure selected is largely driven by individual patient factors and preferences after an informed discussion [4, 16]. The model described here is not anticipated to be a replacement for either endoscopic or surgical treatment, but rather, another option for providers and patients that addresses the limitations of endoscopy. The hybrid approach allows for improved triangulation, more direct control of larger instruments, performance in a non-operating room environment, and utilizes techniques familiar to endoscopists and surgeons.

Disadvantages when compared to endoscopy alone include increased invasiveness inherent to placement of a transgastric port, and the need for gastric wall and skin closure. While no animal in this pilot study experienced severe adverse events, data can be extrapolated from extensive safety data on percutaneously placed endoscopic tubes [17]. Overall, complication rates range from 4.9% to 10.3%, with serious complications occurring in 1.5% to 4% of cases [18]. Major complications to consider include bleeding, perforation, visceral injury (e.g. spleen, liver), necrotizing fasciitis, wound infections, and death. Larger tube diameters have been associated with higher minor complication rates, but it is not clear whether the risk of major complications would be increased [19]. Regardless, care must be taken given the size of the trocar used in the procedure described here. Adhering to well-established best practices to confirm effective and safe placement, including transillumination and palpation, is critical.

To evaluate the efficacy of the stapling procedure, we performed functional lumen imaging of the EGJ. Data are emerging for the use of impedance planimetry to assess and treat a variety of upper gastrointestinal disorders, including GERD [20]. Acknowledging that more data are needed to understand the clinical implications of these measurements, distensibility can help delineate anti-reflux physiologic changes and serve as a proof-of-concept, particularly in the absence of an animal model for GERD. All animals showed a decrease in distensibility post-procedure, which was generally maintained through day 14, albeit to a lesser degree. The observed change in distensibility from baseline, on average was 2.0 mm²/mmHg over the 14 days, is quite robust compared to changes seen in humans who underwent TIF (0.3 to 0.6 mm²/mmHg decrease) [21]. This is likely explained by slight differences in anatomy as well as higher baseline measurements in the porcine model. The encouraging change in distensibility was seen in all animals, but did not quite reach a level of significance due to the small sample size.

At procedure completion, the technique used to close the gastrostomy site is not trivial when considering the defect created by a full-sized, 12-mm port. Prior iterations of the PIT de-

vice employed crossing, full-thickness sutures that were passed from the skin into the stomach with endoscopic assistance [1]. This was somewhat time-intensive, and the use of an OTSC was felt to be simpler and more efficient. The results from necropsy suggest it was effective when paired with standard cutaneous skin closure. While no incisional hernias were noted in this small cohort, the current platform lacks fascial closure, which is felt to be necessary for all ports greater than 10 mm in size based on surgical literature [22, 23]. Future optimization of the PIT device would ideally allow for miniaturization with a dedicated stapler or incorporation of a dedicated fascial closure system.

Limitations of this study include its small sample size, use of an animal model, surrogate anti-reflux assessment with functional lumen imaging data, and a relatively short follow-up duration of 14 days. While the porcine EGJ is remarkably similar to humans, including its innervation and fiber orientation [24], care must be taken when extrapolating results as key differences include orientation, increased mural thickness, and a shorter lesser curvature, which may exaggerate anti-reflux effects [25].

Conclusions

In conclusion, this study demonstrates successful use of an intragastric trocar to more simply perform an otherwise complex and technically demanding anti-reflux procedure using a laparoscopic stapler. We also highlight a novel approach to therapeutic procedures being performed in a combined endoscopic/laparoscopic environment governed by the gastroenterologist. Further investigation and refinement of this technique is anticipated to optimize minimally invasive, endoluminal treatment of GERD in humans.

Competing interests

Dr. Abu Dayyeh reports consultant roles with Endogenex, Endo-TAGSS, Metamodix, and BFKW; consultant and grant or research support from USGI, Cairn Diagnostics, Aspire Bariatrics, Boston Scientific; speaker roles with Olympus, Johnson and Johnson; speaker and grant or research support from Medtronic, Endogastric solutions; and research support from Apollo Endosurgery and Spatz Medical. Dr. Storm has received research grant support from Apollo Endosurgery, Boston Scientific, Endogenex, Endo-TAGSS, and Enterasense. He is a consultant for Apollo Endosurgery, ERBE, GI Dynamics, Intuitive Surgical, and Olympus. The remaining authors have no conflicts to disclose.

Funding

endo-TAGSS, LLC

References

- [1] Storm AC, Aihara H, Skinner MJ et al. Long-term successful closure of a percutaneous intragastric trocar tract with crossing full-thickness sutures in a porcine model. *Endoscopy* 2018; 50: 626–630

- [2] Storm AC, Aihara H, Thompson CC. Novel intragastric trocar placed by PEG technique permits endolumenal use of rigid instruments to simplify complex endoscopic procedures. *Gastrointest Endosc* 2016; 84: 518–522
- [3] Storm AC, Aihara H, Skinner MJ et al. A simply placed percutaneous intragastric trocar for use of laparoscopic tools in endoscopy. *Gastrointest Endosc* 2016; 84: 1051–1052
- [4] Katz PO, Dunbar KB, Schnoll-Sussman FH et al. ACG Clinical Guideline for the Diagnosis and Management of Gastroesophageal Reflux Disease. *Am J Gastroenterol* 2022; 117: 27–56
- [5] Huang X, Chen S, Zhao H et al. Efficacy of transoral incisionless fundoplication (TIF) for the treatment of GERD: a systematic review with meta-analysis. *Surg Endosc* 2017; 31: 1032–1044
- [6] Su B, Dunst C, Gould J et al. Experience-based expert consensus on the intra-operative usage of the Endoflip impedance planimetry system. *Surg Endosc* 2021; 35: 2731–2742
- [7] Ilcyszyn A, Botha AJ. Feasibility of esophagogastric junction distensibility measurement during Nissen fundoplication. *Dis Esophagus* 2014; 27: 637–644
- [8] Perretta S, Dallemagne B, McMahon B et al. Video. Improving functional esophageal surgery with a “smart” bougie: Endoflip. *Surg Endosc* 2011; 25: 3109
- [9] Hoppo T, McMahon BP, Witteman BPL et al. Functional lumen imaging probe to assess geometric changes in the esophagogastric junction following endolumenal fundoplication. *J Gastrointest Surg* 2011; 15: 1112–1120
- [10] Rinsma NF, Smeets FG, Bruls DW et al. Effect of transoral incisionless fundoplication on reflux mechanisms. *Surg Endosc* 2014; 28: 941–949
- [11] Ohashi S. Laparoscopic intraluminal (intra-gastric) surgery for early gastric cancer: A new concept in laparoscopic surgery. *Surg Endosc* 1995; 9
- [12] Tonouchi H, Mohri Y, Tanaka K et al. Laparoscopic intragastric surgery using GelPort. *J Laparoendoscop Adv Surg Tech* 2006; 16: 146–148
- [13] Walsh R. Combined endoscopic/laparoscopic intragastric resection of gastric stromal tumors. *J Gastrointest Surg* 2003; 7: 386–392
- [14] Sahn M, Pross M, Lippert H. Intraluminal resection of gastric tumors using intragastric trocar technique. *Surg Laparosc Endosc Percutan Tech* 2011; 21: e169–e172
- [15] Zhang H, Chen J, Chen C. The efficacy and safety of laparoscopy combined with gastroscopy positioning in treating gastric stromal tumours: A systematic review and meta-analysis. *J Minim Access Surg* 2021; 17: 147
- [16] Khashab MA, Vela MF, Thosani N et al. ASGE guideline on the management of achalasia. *Gastrointest Endosc* 2020; 91: 213–227
- [17] Rahnemai-Azar AA, Rahnemaiazar AA, Naghshizadian R et al. Percutaneous endoscopic gastrostomy: Indications, technique, complications and management. *World J Gastroenterol* 2014; 20: 7739–7751
- [18] Jain R, Maple JT, Anderson MA et al. The role of endoscopy in enteral feeding. *Gastrointestinal Endoscopy* 2011; 74: 7–12
- [19] Park S-K, Kim JY, Koh S-J et al. Complications of percutaneous endoscopic and radiologic gastrostomy tube insertion: a KASID (Korean Association for the Study of Intestinal Diseases) study. *Surg Endosc* 2019; 33: 750–756
- [20] Hirano I, Pandolfino J, Boeckxstaens G. Functional lumen imaging probe for the management of esophageal disorders: expert review from the Clinical Practice Updates Committee of the AGA Institute. *Clin Gastroenterol Hepatol* 2017; 15: 325–334
- [21] Smeets FGM, Keszhelyi D, Bouvy ND et al. Does measurement of esophagogastric junction distensibility by EndoFLIP predict therapy-responsiveness to endoluminal fundoplication in patients with gastroesophageal reflux disease? *J Neurogastroenterol Motil* 2015; 21: 255–264
- [22] Helgstrand F, Rosenberg J, Bisgaard T. Trocar site hernia after laparoscopic surgery: a qualitative systematic review. *Hernia* 2011; 15: 113–121
- [23] Shaher Z. Port closure techniques. *Surg Endosc* 2007; 21: 1264–1274
- [24] Vegesna AK, Braverman AS, Miller LS et al. Comparison of human and porcine gastric clasp and sling fiber contraction by M2 and M3 muscarinic receptors. *Am J Physiol Gastrointest Liver Physiol* 2010; 298: G530–G534
- [25] Chung H, Kim SH, Shin SK. A potential simple endoscopic antireflux method, “the Ripple Procedure” to reduce distensibility at the esophagogastric junction in a porcine model. *Surg Endosc* 2020; 34: 5017–5022